

# Tachycardie Ventriculaire

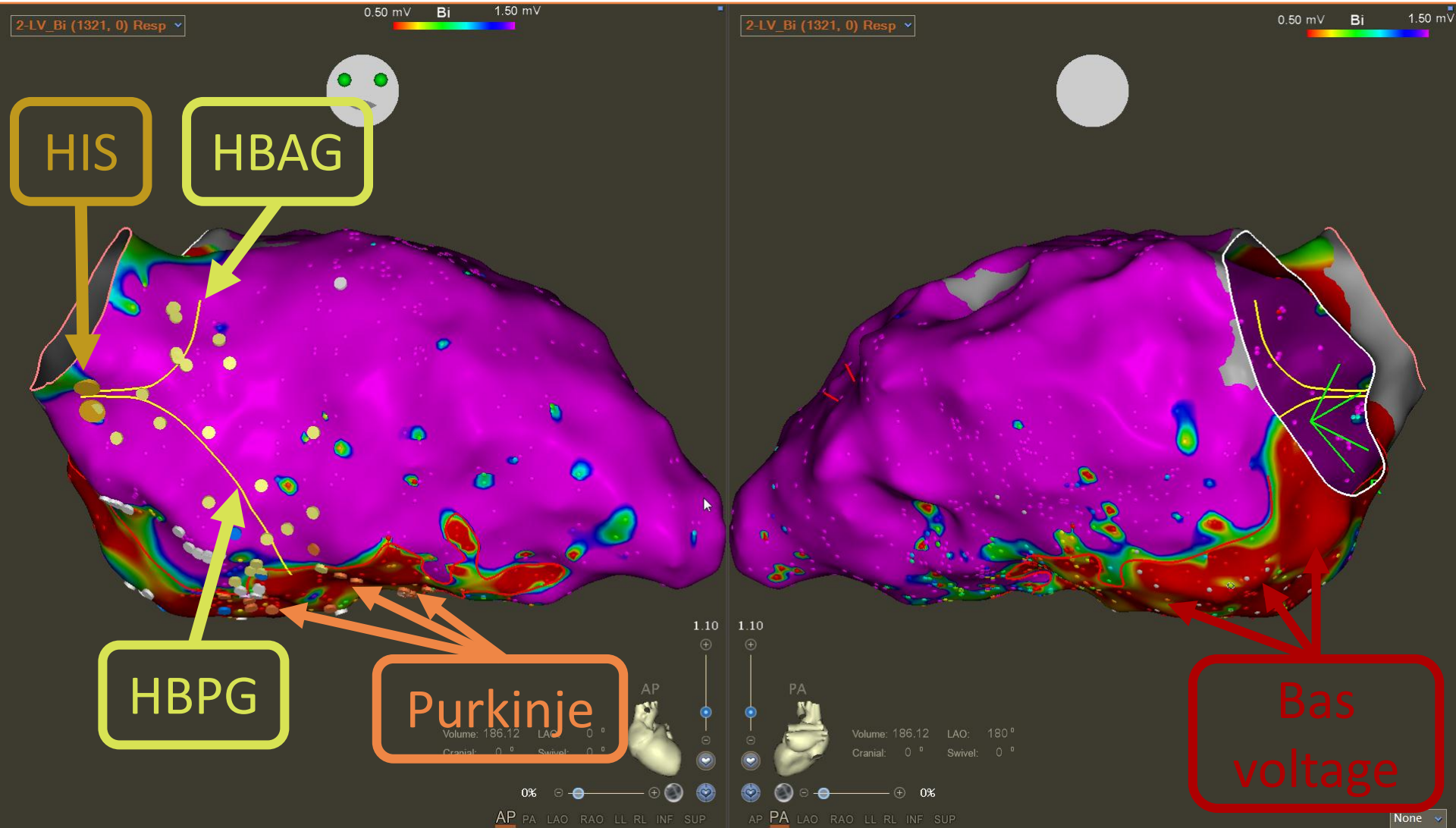
Dr Durand & Dr Rosier

Décembre 2019 - Infirmerie Protestante

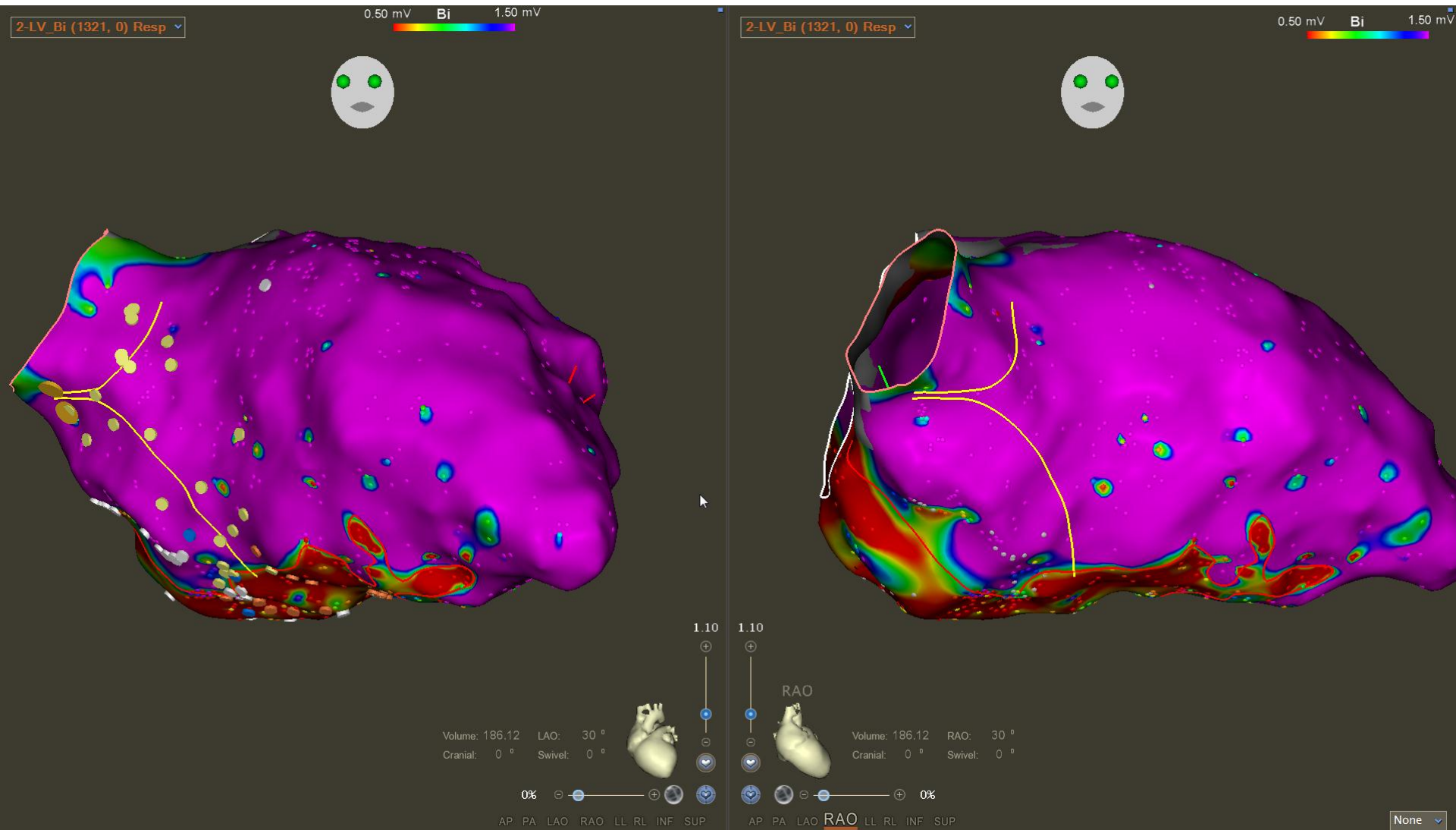
# Patient

- Terrain : homme, 72 ans
- ATCD :
  - Cardiopathie Ischémique : ATCD d'IDM inférobasal
  - Défibrillateur en prévention primaire
- HDLM :
  - TV récidivantes traitées par ATP/choc

# APPA - carte de voltage



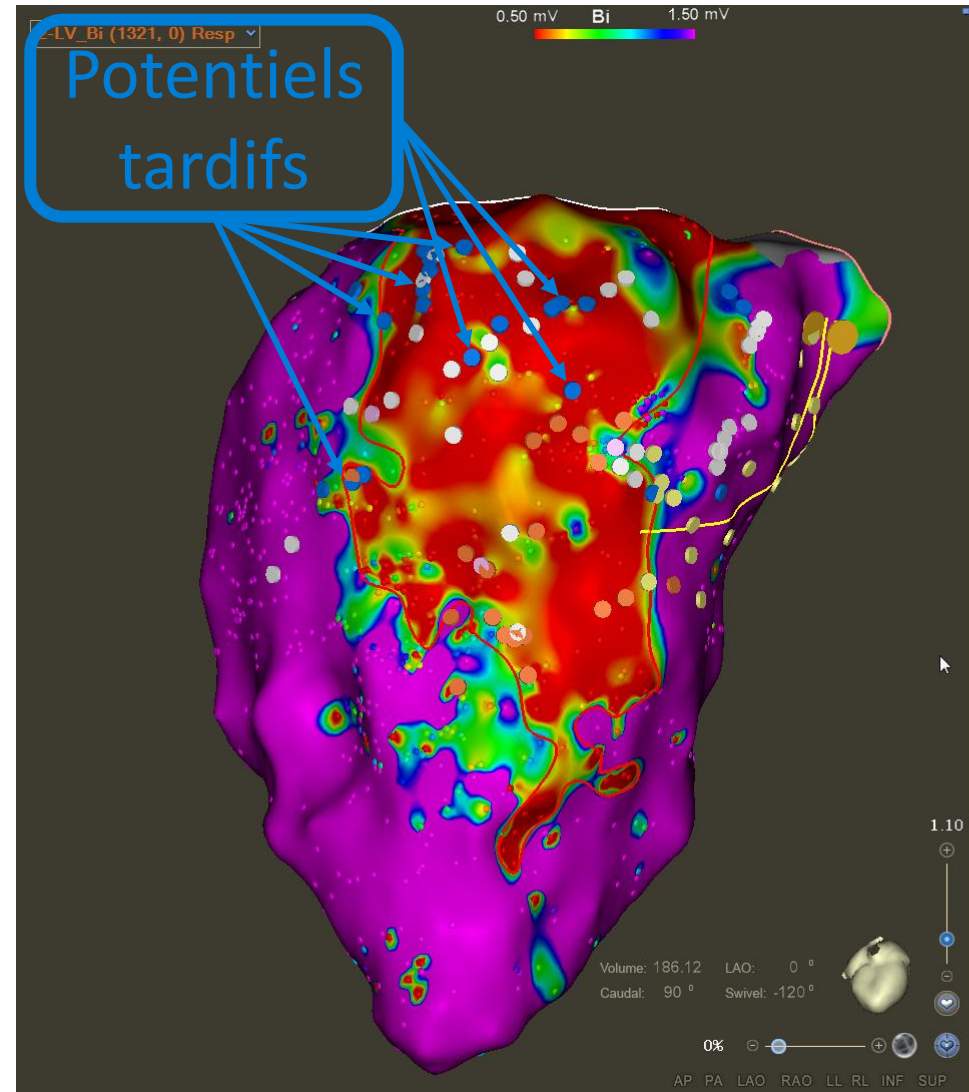
# OAD/OAG - carte de voltage



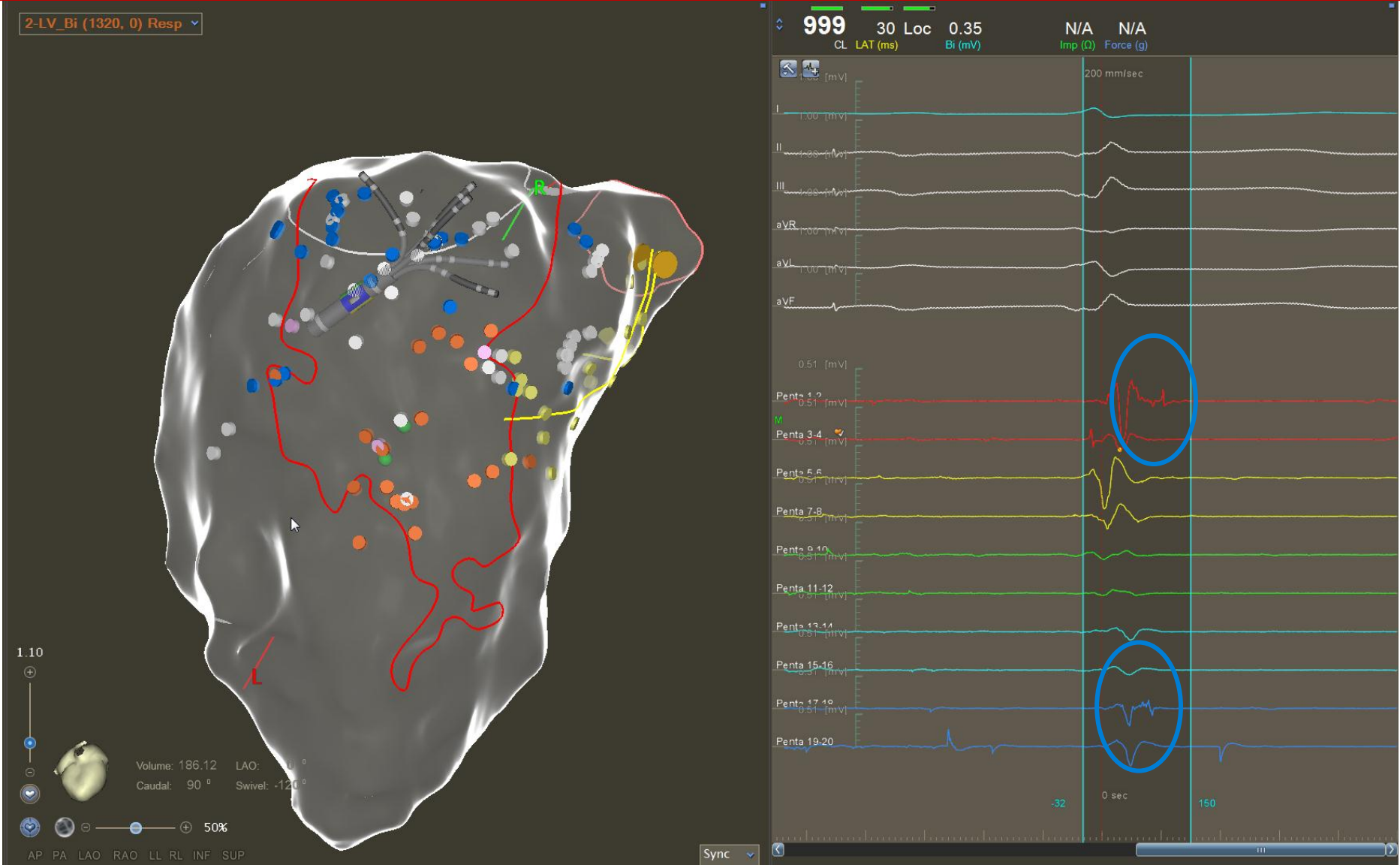

# Vue inférieure - carte de voltage

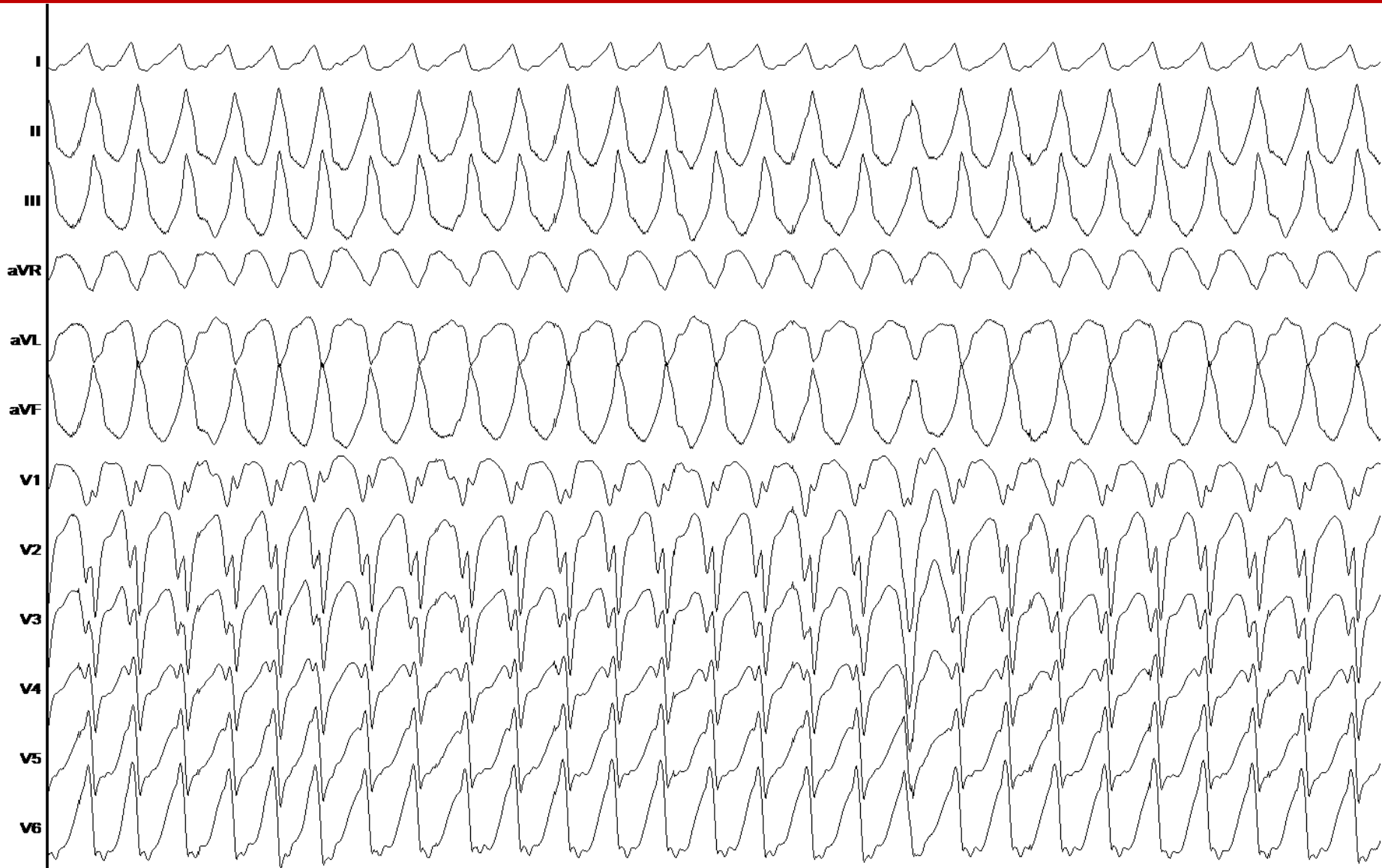- Bas voltage & Potentiels tardifs
  - Inféro-basal
  - Inféro-median



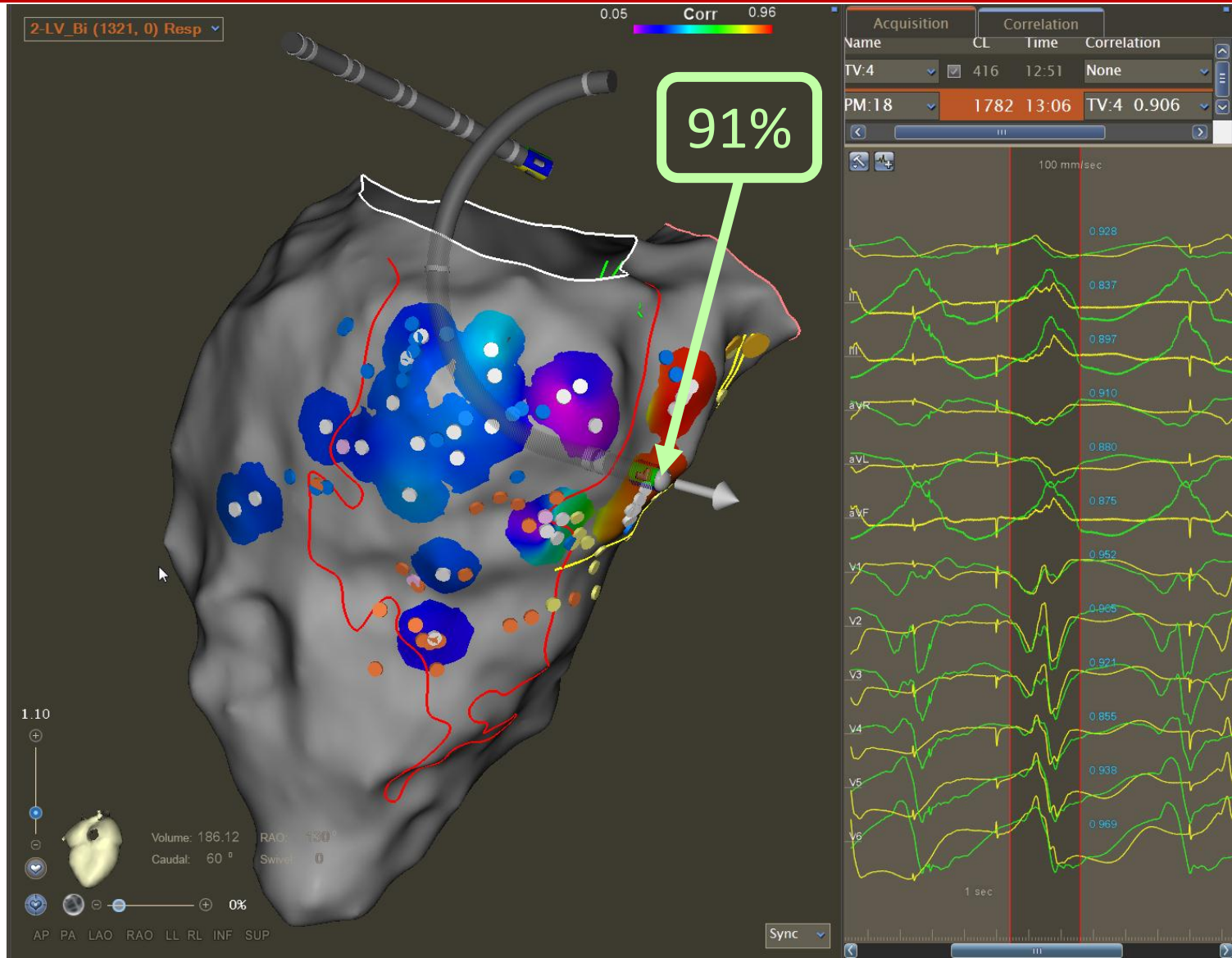# Vue inférieure – Potentiels tardifs



# Stimulation programmée – TV1

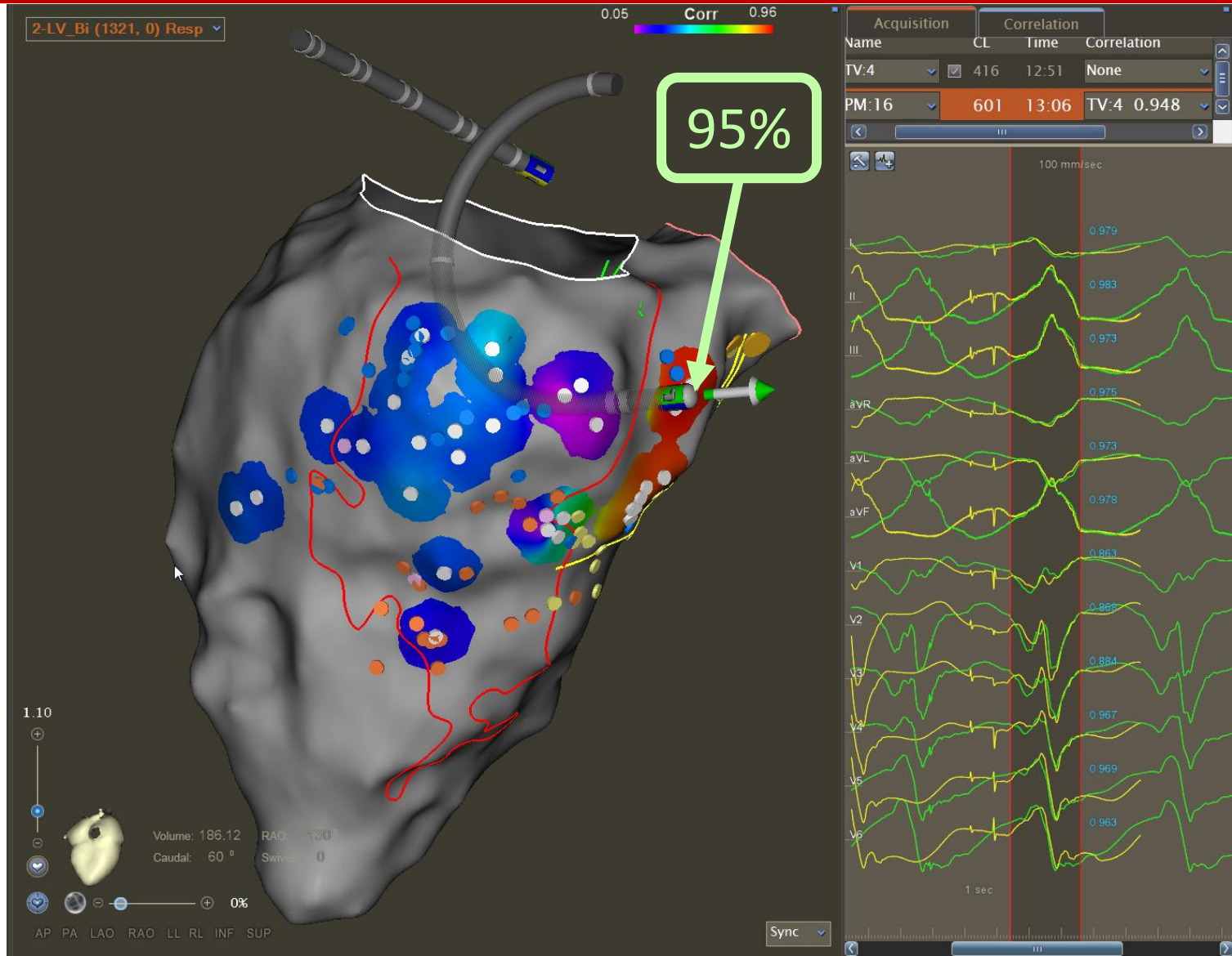

# TV1 – Carte de Pace-mapping

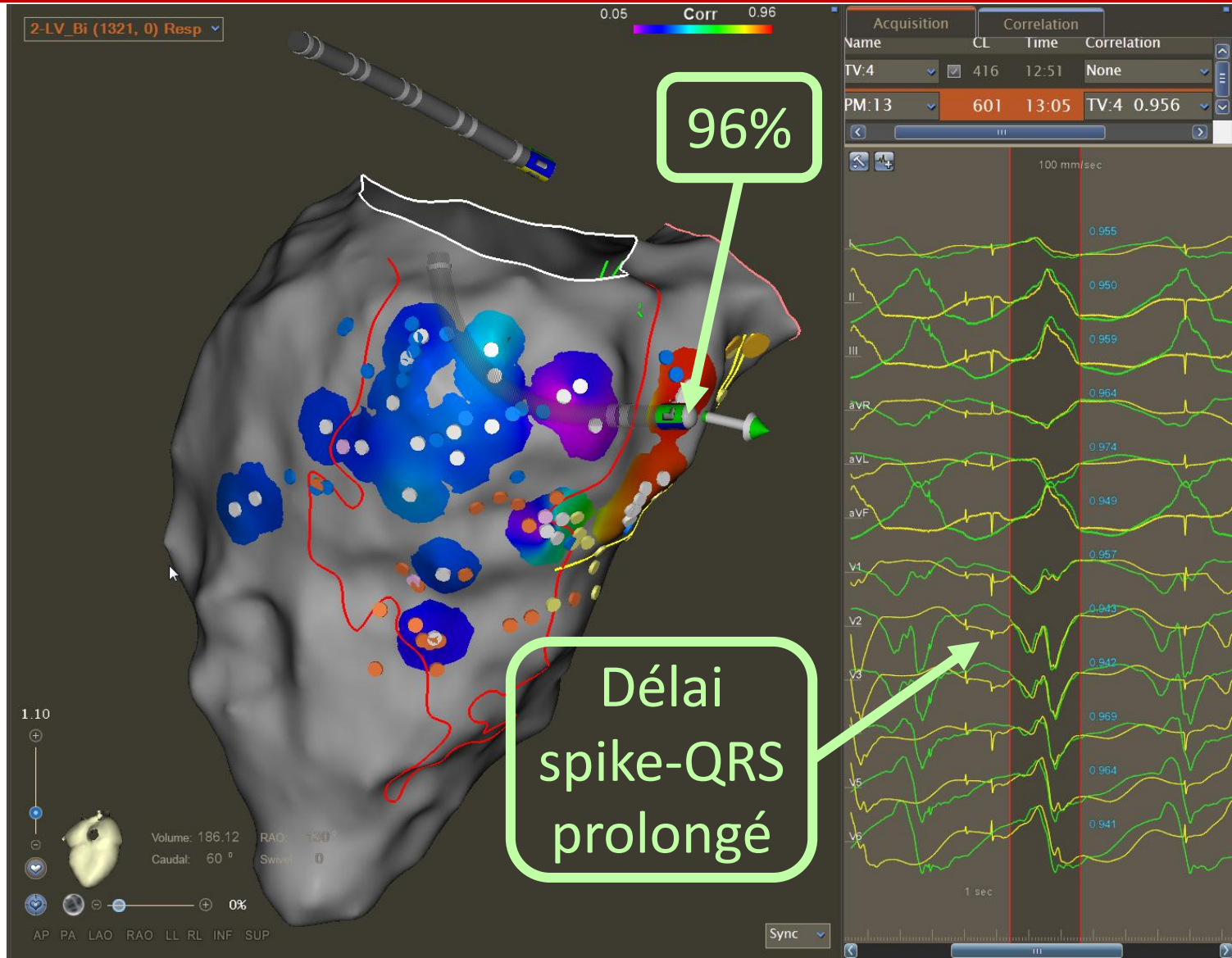




# TV1 – Carte de Pace-mapping

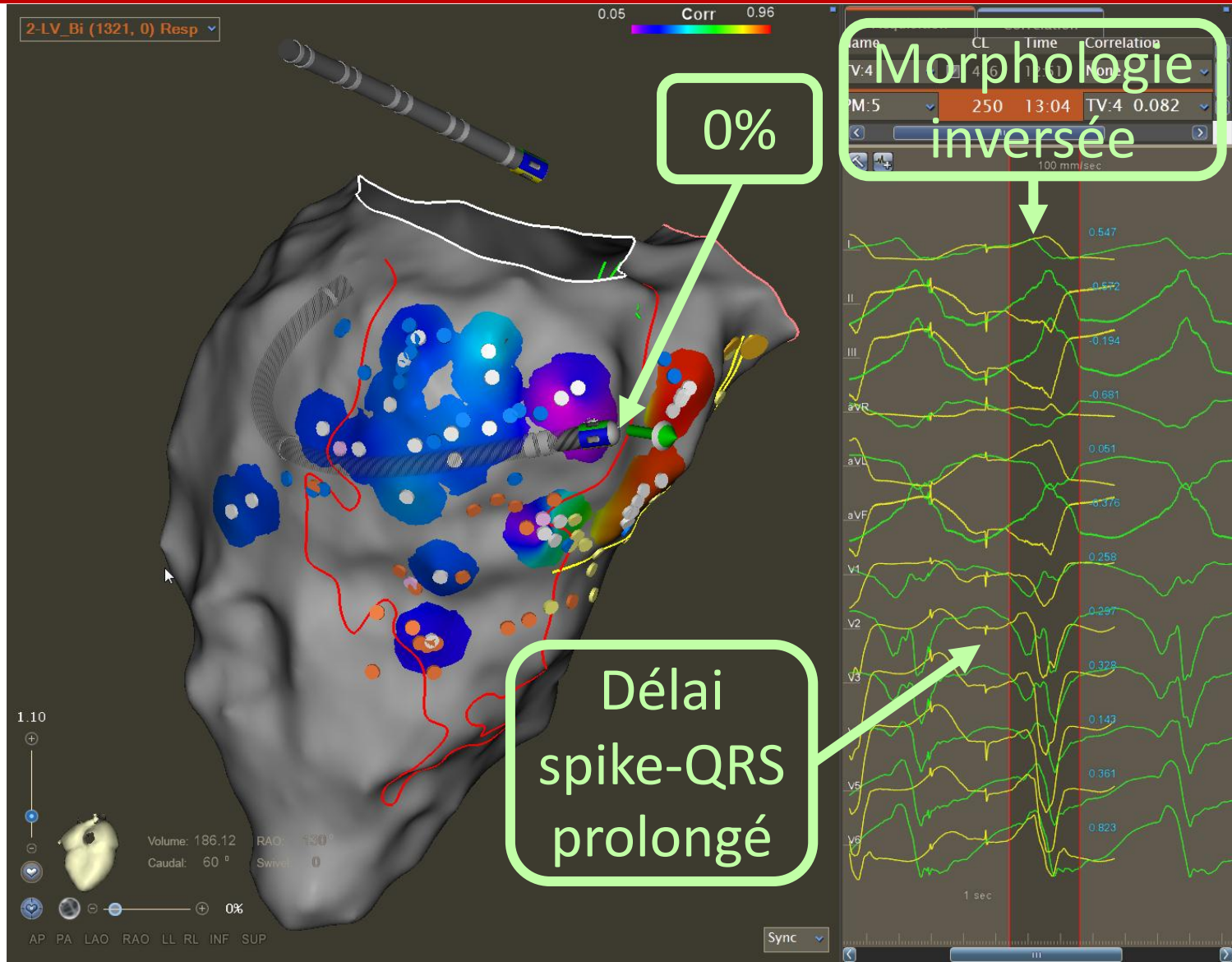


# TV1 – Carte de Pace-mapping

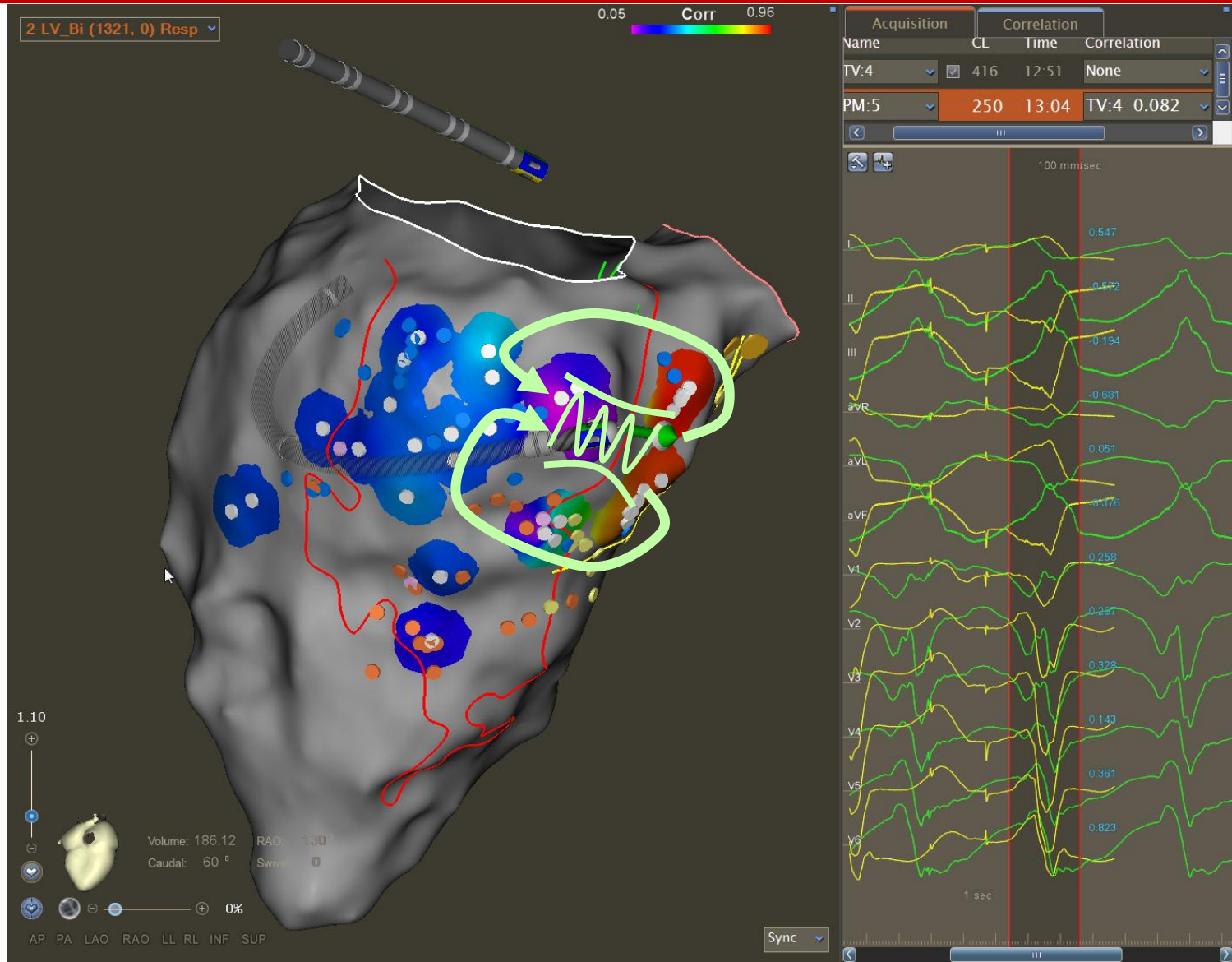




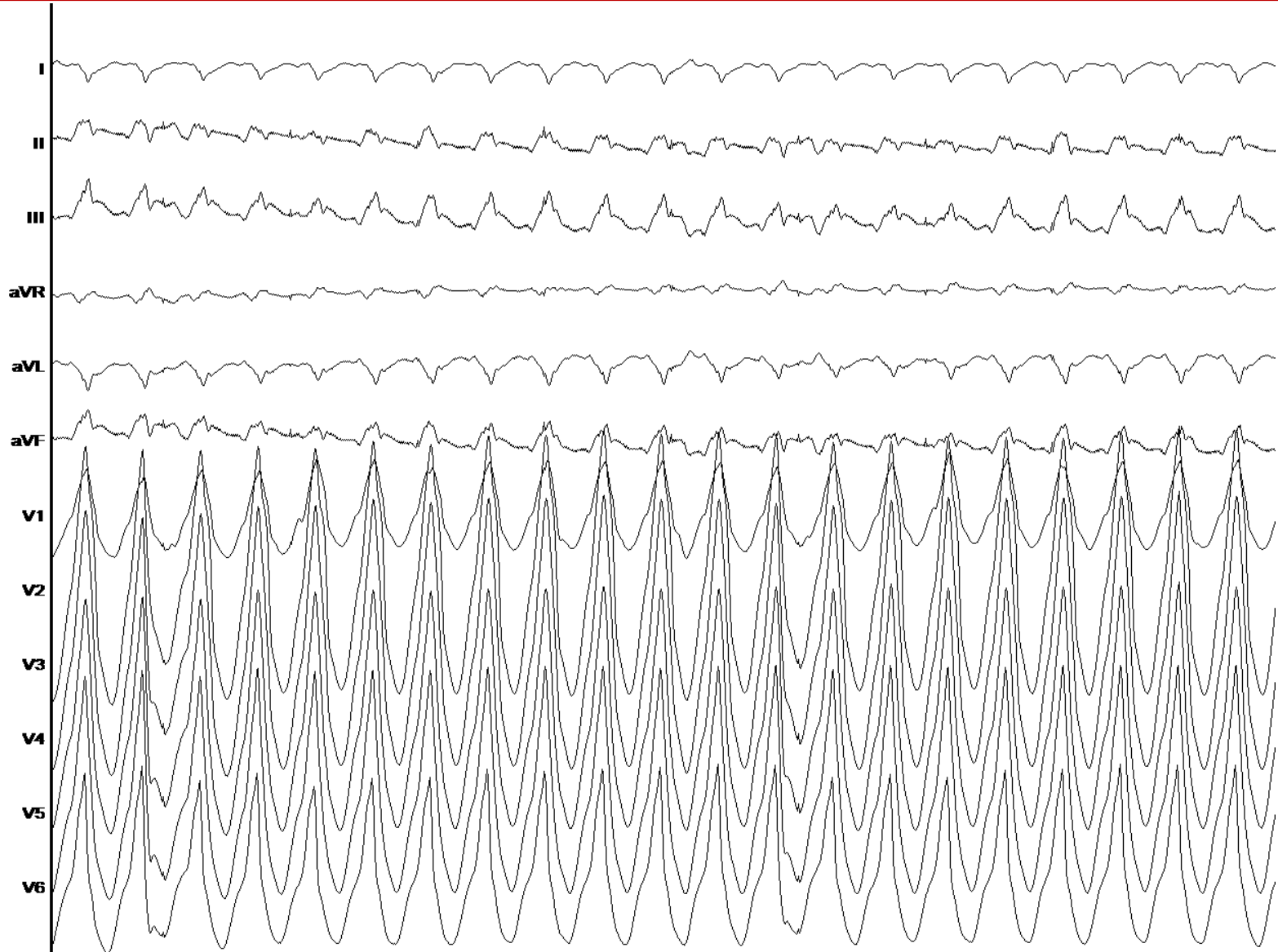
# TV1 – Carte de Pace-mapping



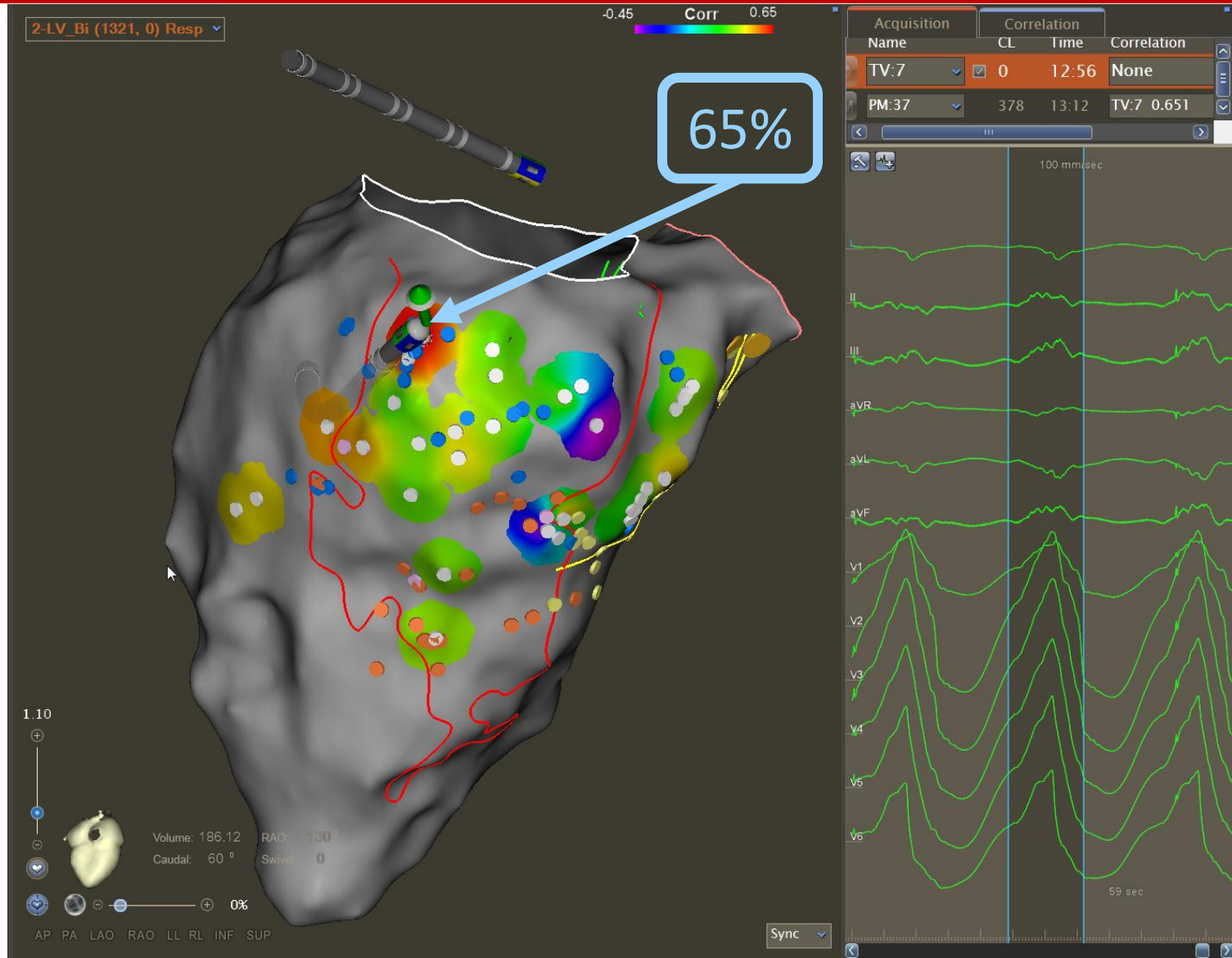
# TV1 – Isthme



# Stimulation programmée – TV2

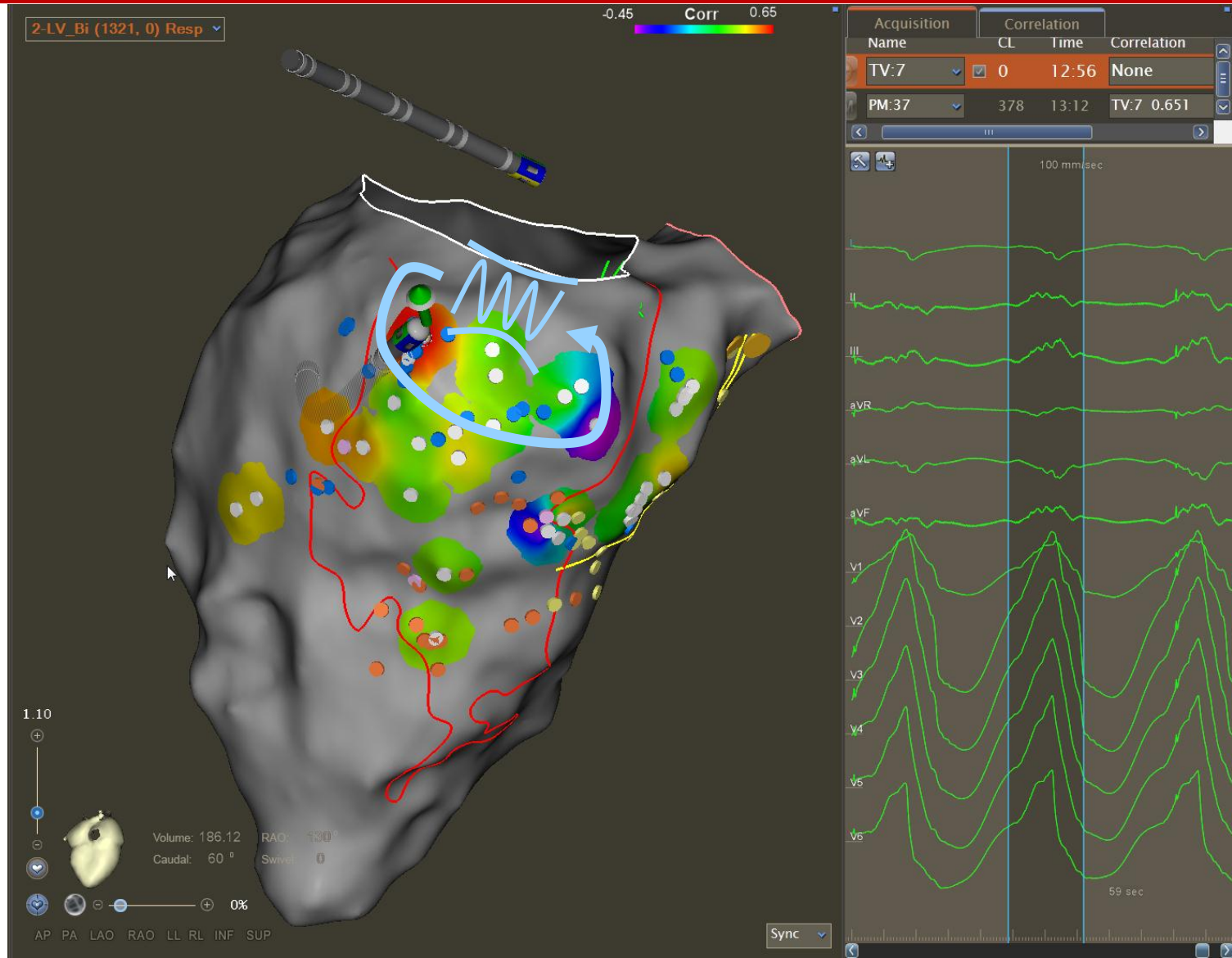


# TV2 – Carte de Pace-mapping

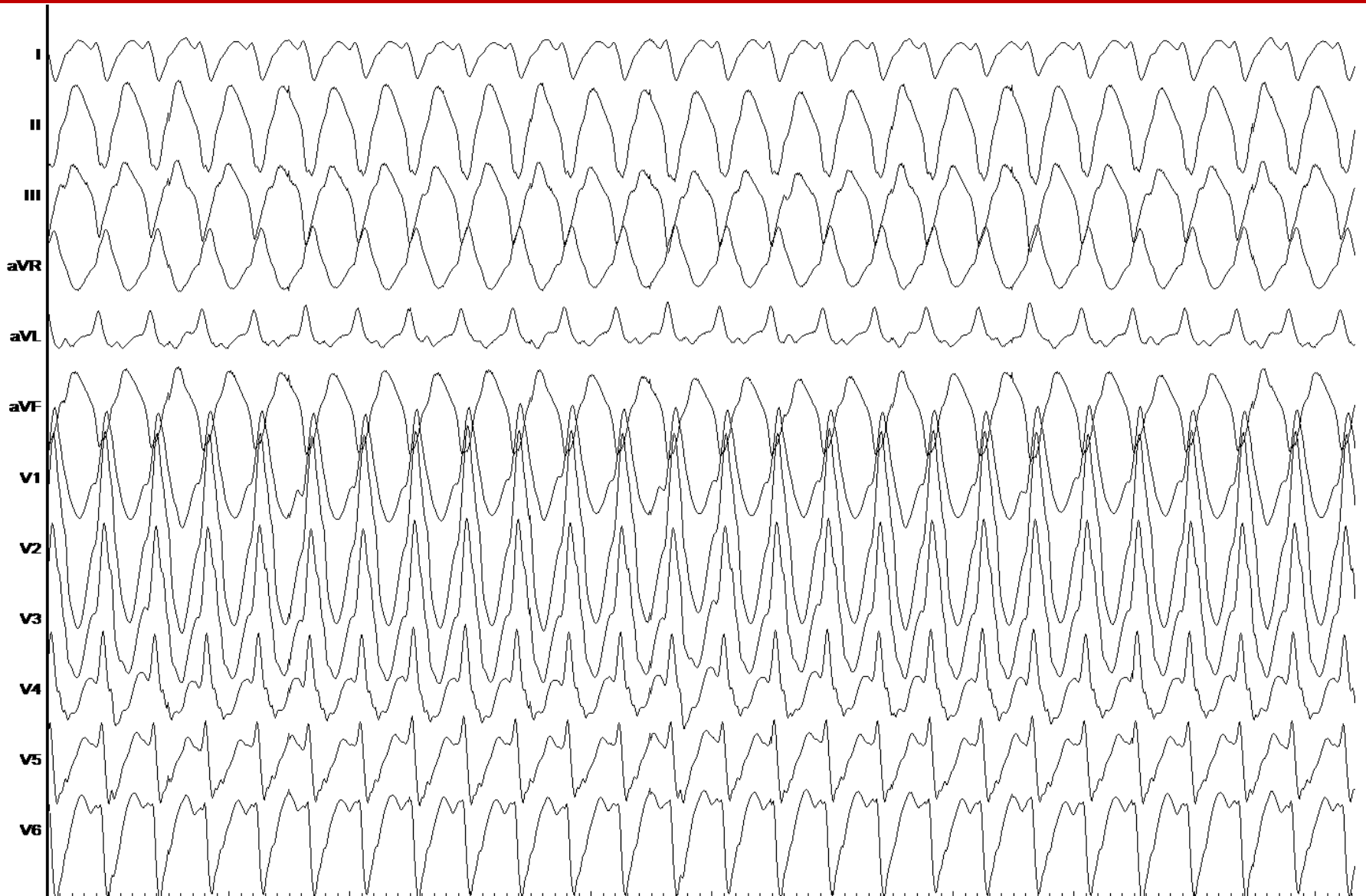



# TV2 – Isthme

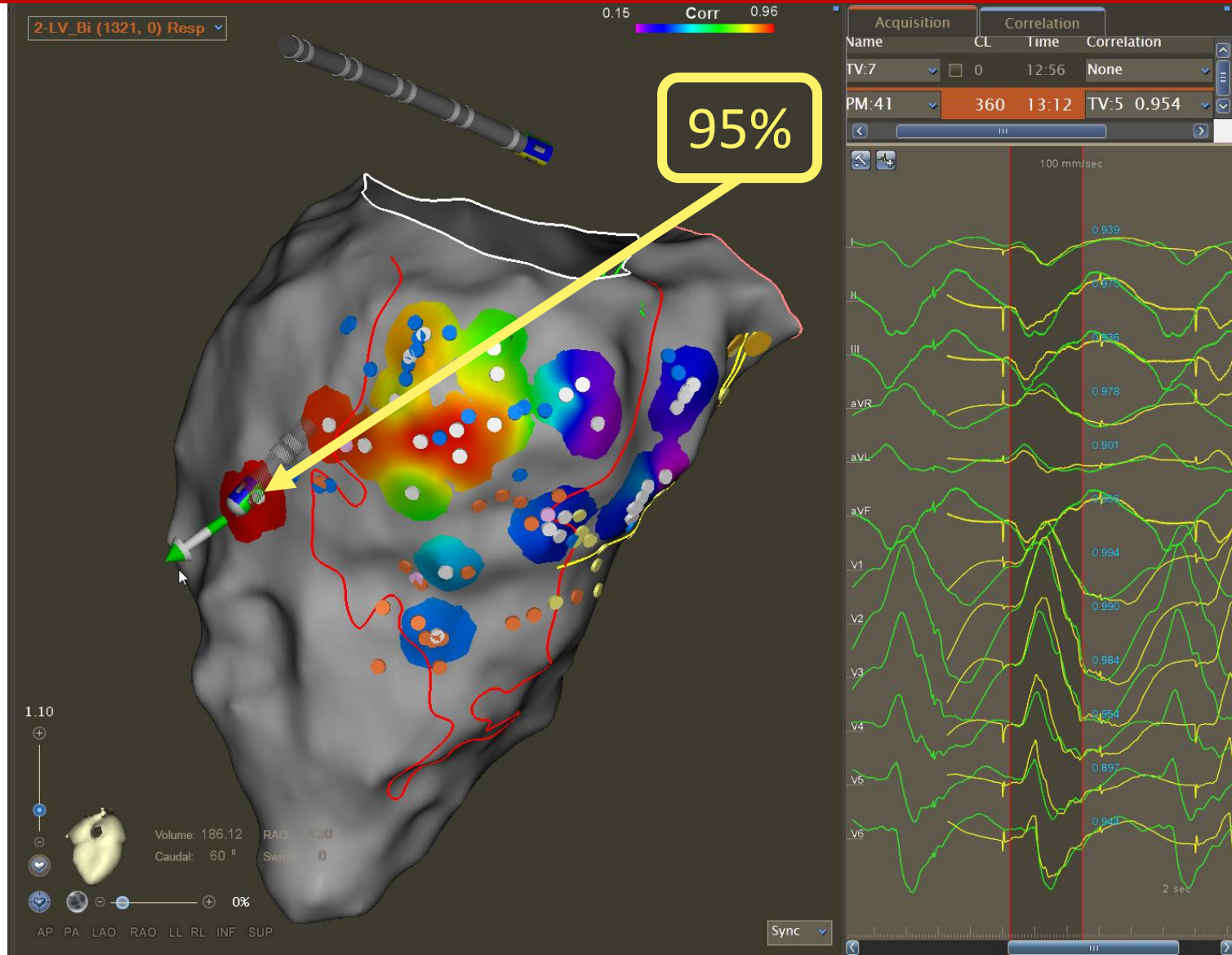

# Stimulation programmée – TV3

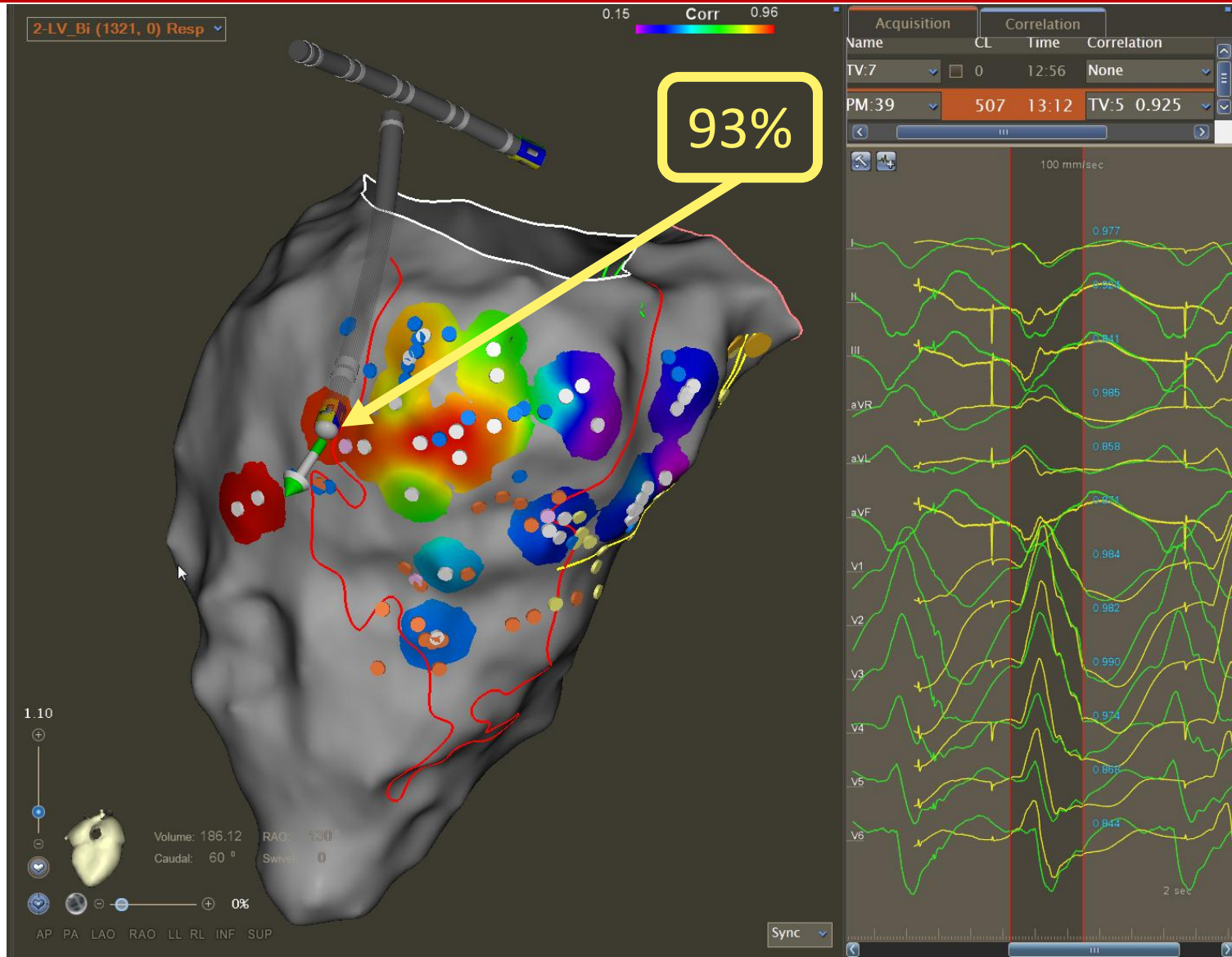




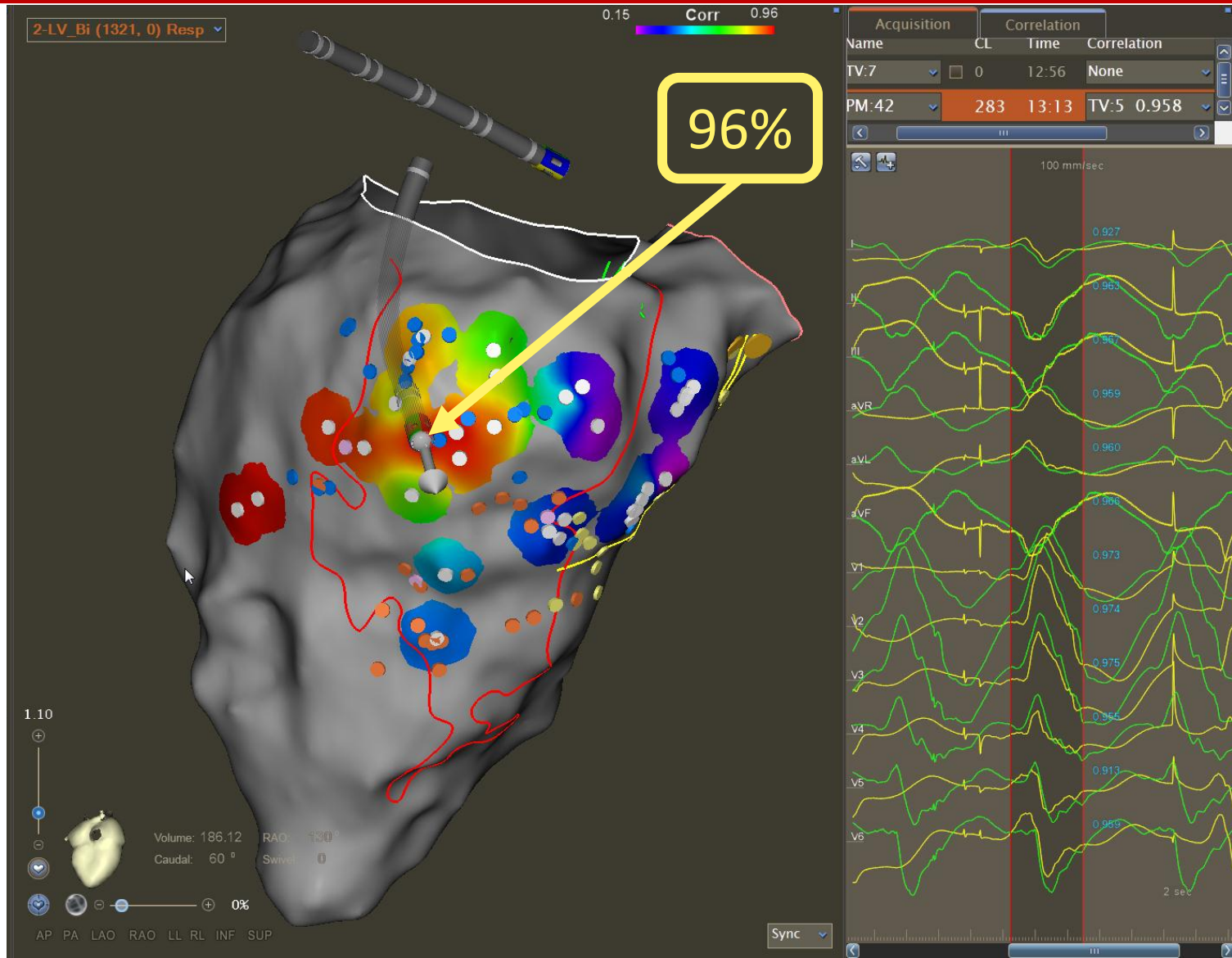
# TV3 – Carte de Pace-mapping



# TV3 – Carte de Pace-mapping

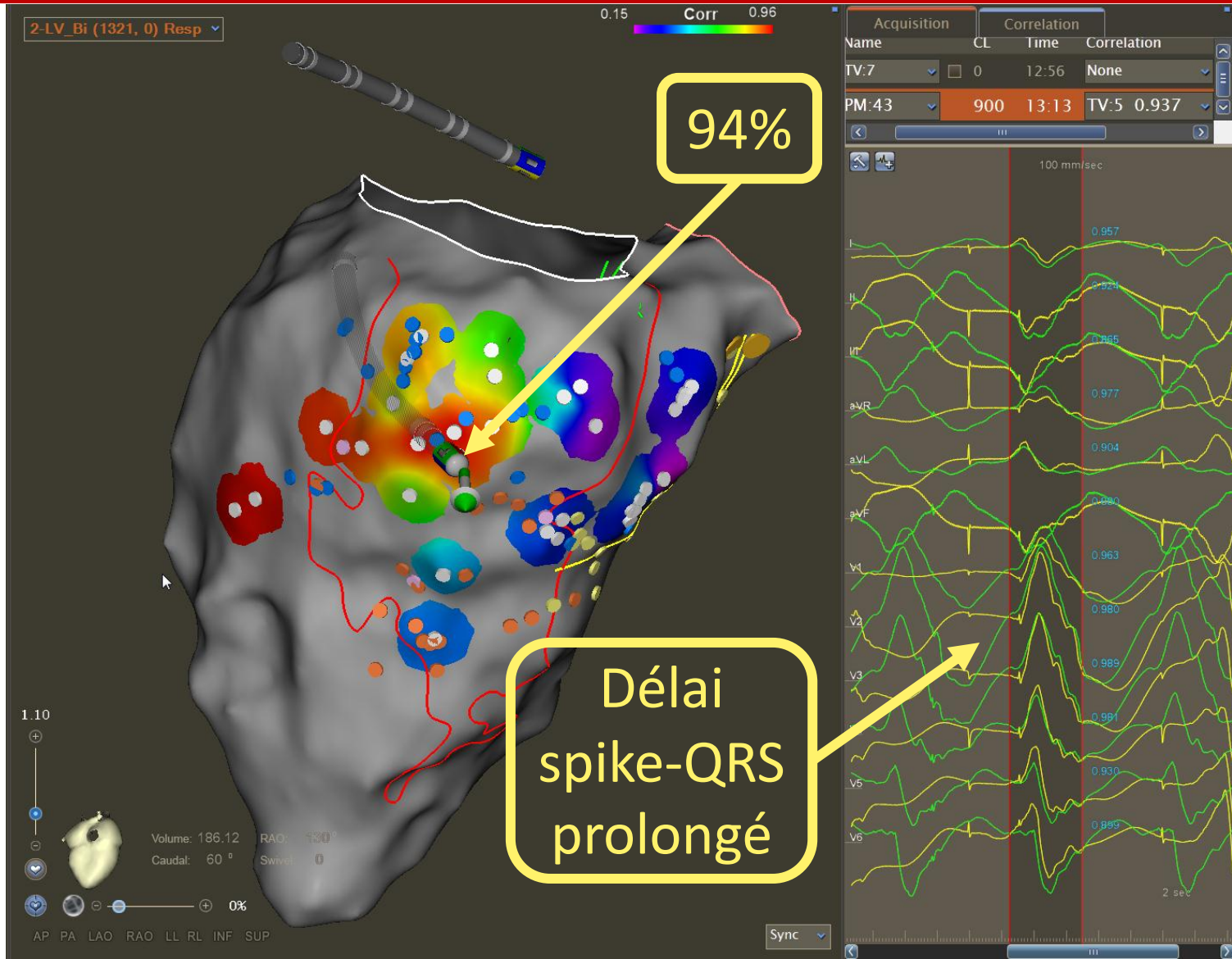


# TV3 – Carte de Pace-mapping

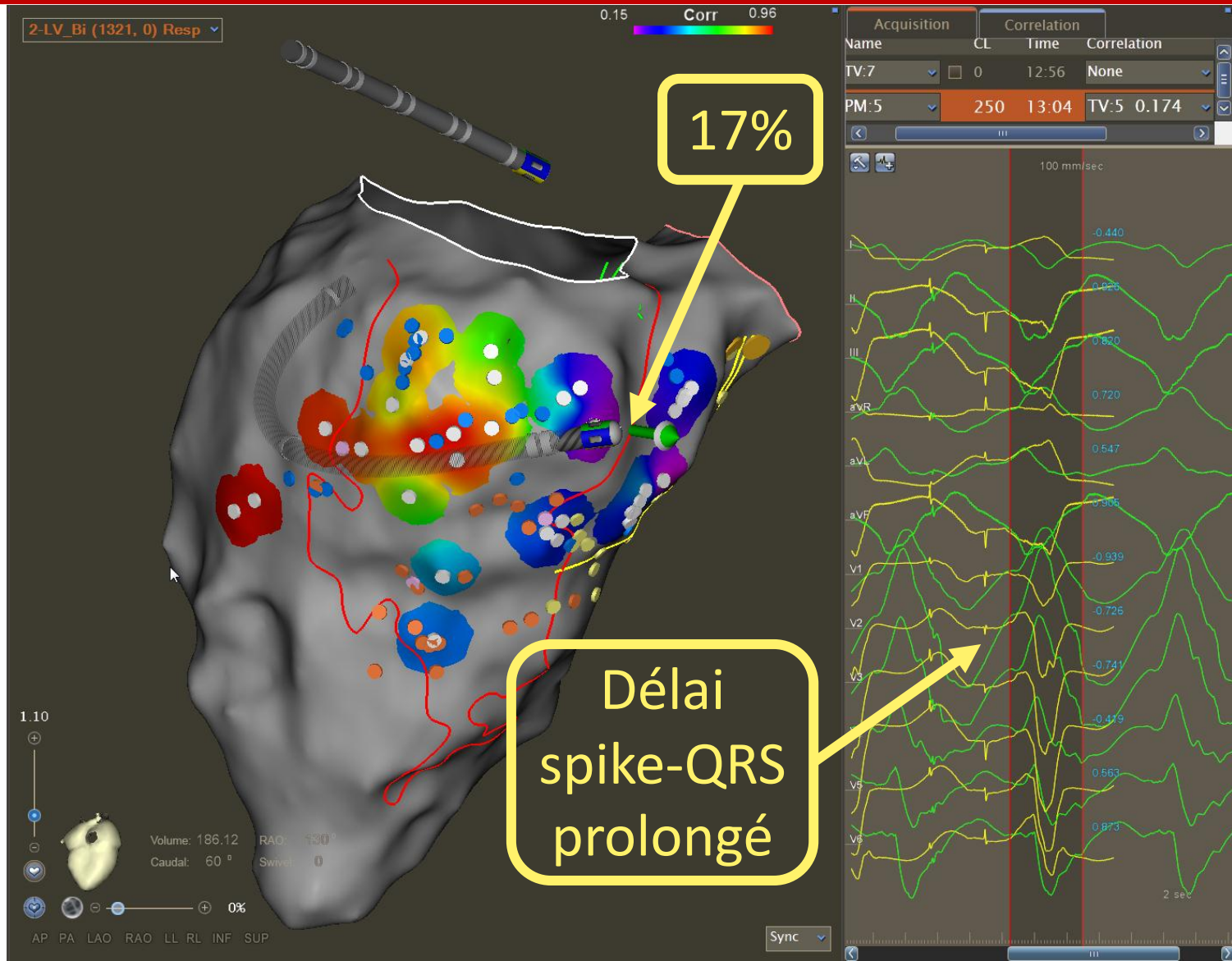




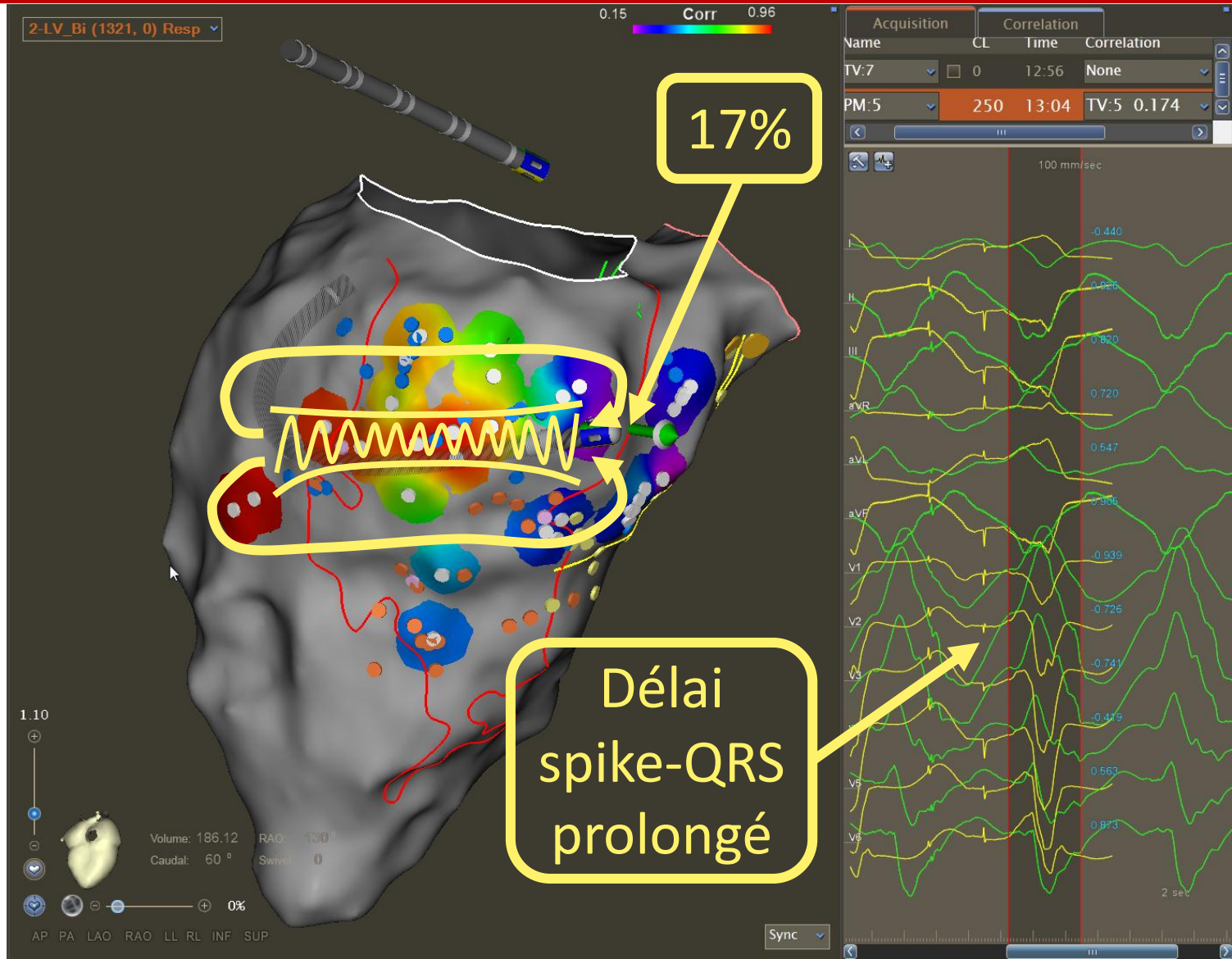
# TV3 – Carte de Pace-mapping



# TV3 – Carte de Pace-mapping

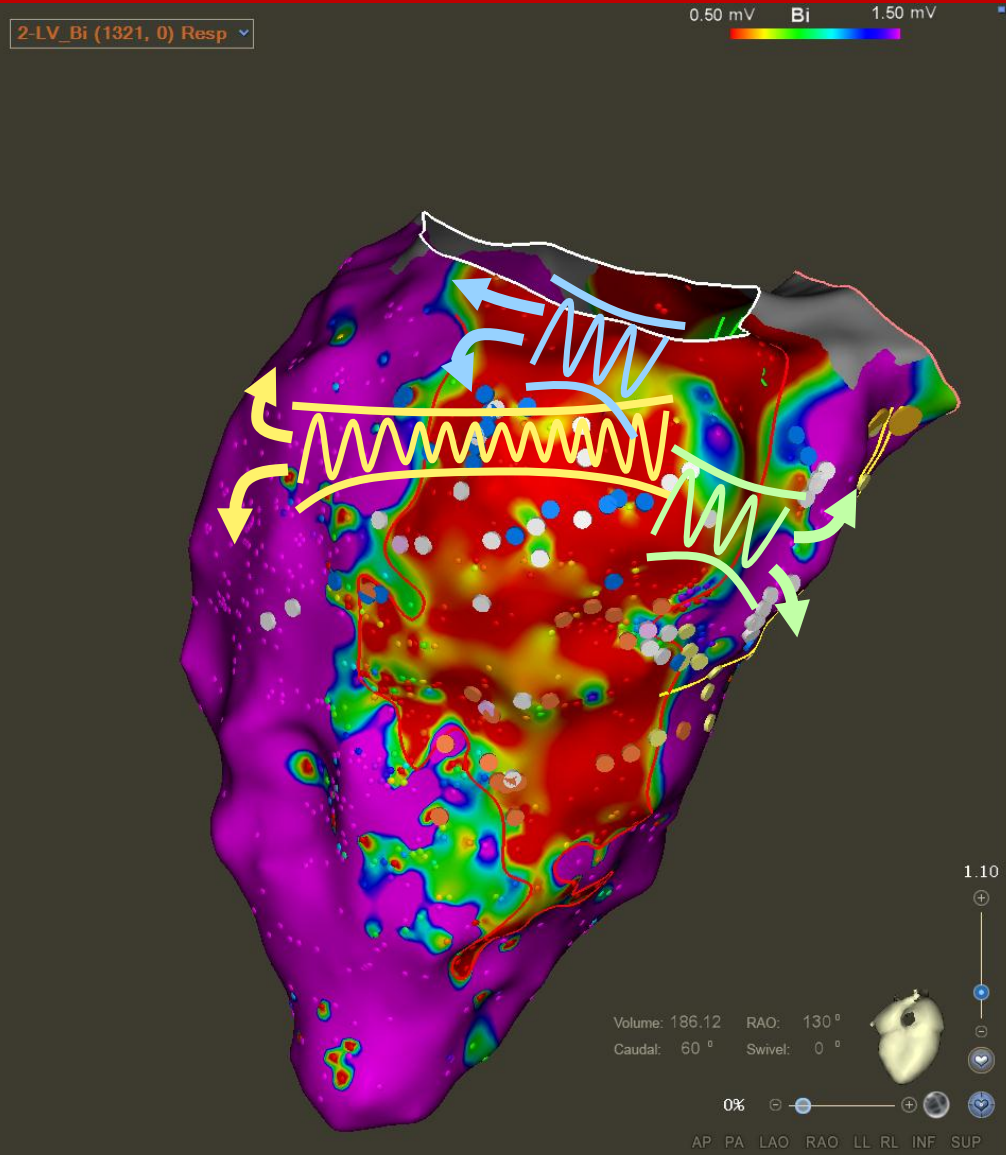
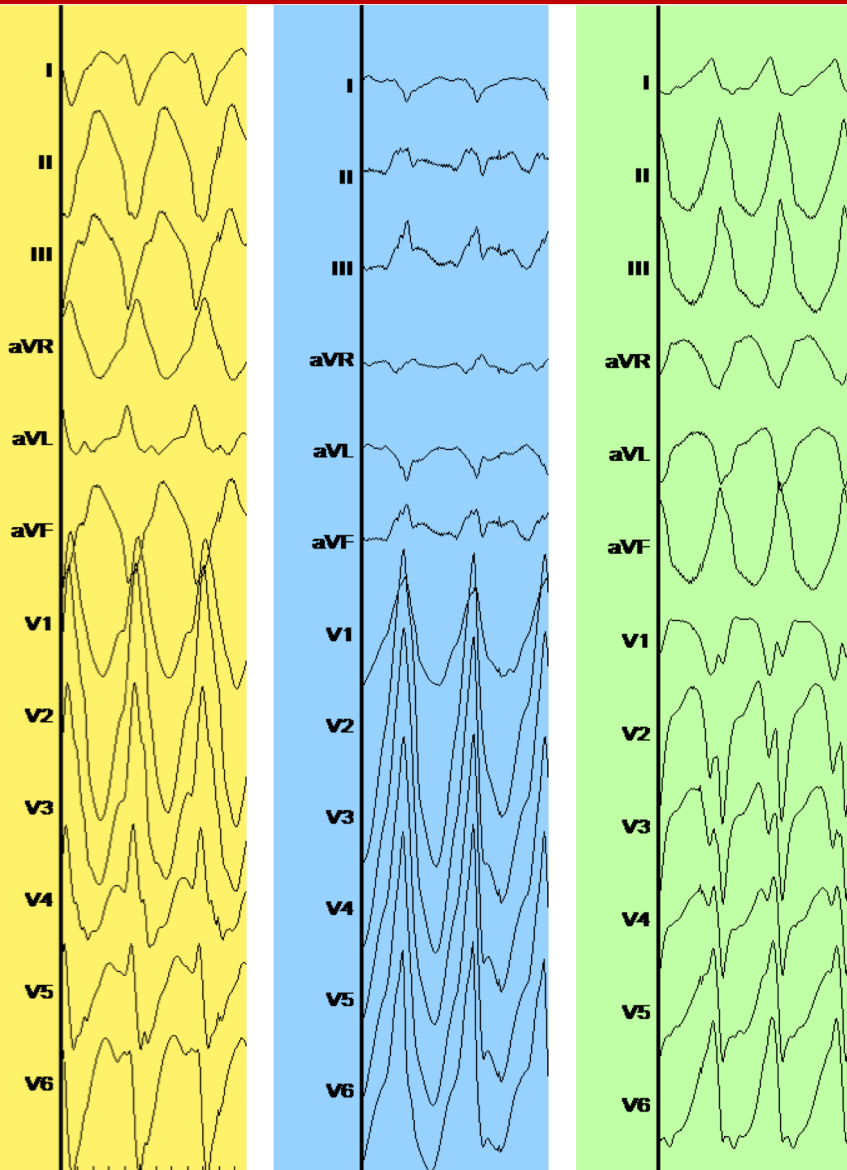


# TV3 – Isthme



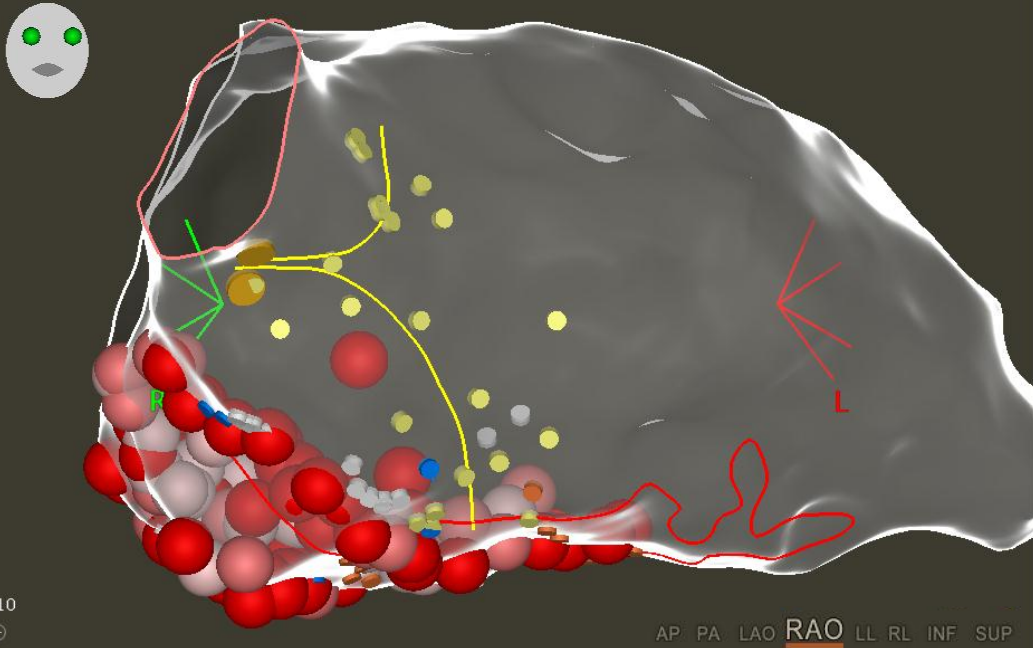
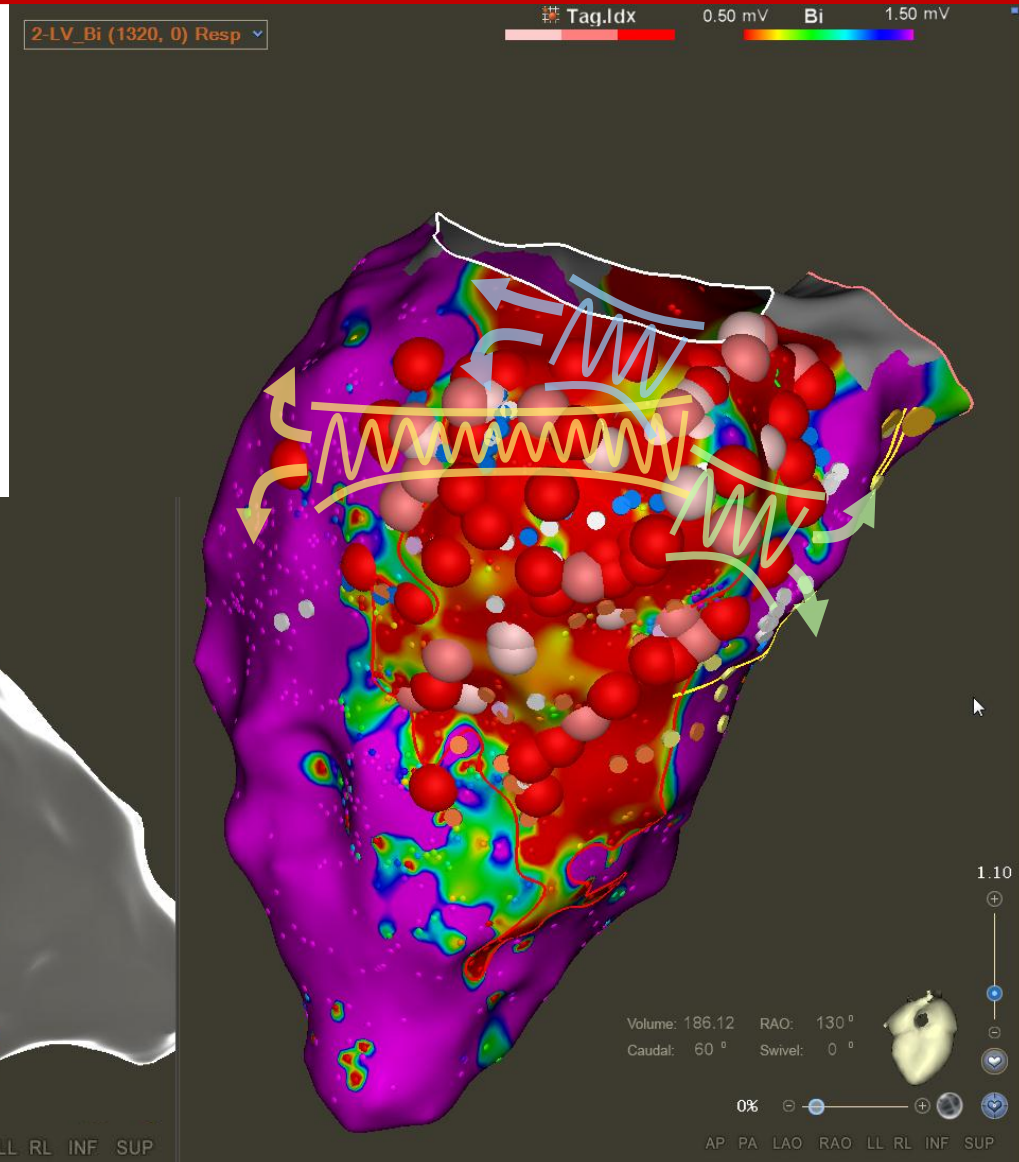


# Carte de Pace-mapping - Bilan



# Ablation

- 50W
- Stratégie
  - Potentiels tardifs
  - Isthmes TV1 TV2 TV3
  - Homogénéisation de la cicatrice
  - Préserver les voies de conduction



# Résumé

- **Abord Transseptal:**
  - Gaine Mullins (Abbott)
- **Ablation :**
  - 20:30 min de RF
  - 62 kJ de RF
- **Matériel :**
  - Pentaray Orange (Biosense)
  - Decanav Orange (Biosense)
  - STSF Noire (Biosense)

